

Case Report

# Bilateral Ovarian Mature Teratoma in a Middle-Aged Female: A Rare Entity

Josephain K<sup>1</sup>; Arundhathi Shankaralingappa<sup>2\*</sup>; Sharmila Vijayan<sup>3</sup>; Priyanka Yoga Purini<sup>4</sup>

<sup>1</sup>Senior Resident, Department of Pathology, All India Institute of Medical Sciences, Mangalagiri, India.

<sup>2</sup>Associate Professor of Pathology, All India Institute of Medical Sciences, Mangalagiri, India.

<sup>3</sup>Additional Professor of Obstetrics & Gynaecology, All India Institute of Medical Sciences, Mangalagiri, India.

<sup>4</sup>Assistant Professor of Obstetrics & Gynaecology, All India Institute of Medical Sciences, Mangalagiri, India.

**\*Corresponding Author: Arundhathi Shankaralingappa**

Associate Professor of Pathology, All India Institute of Medical Sciences, Mangalagiri, India.

Email: arundhathi19@yahoo.co.in

**Article Info**

Received: Jul 04, 2023

Accepted: Jul 21, 2023

Published: Jul 28, 2023

Archived: www.jclinmedsurgery.com

Copyright: © Shankaralingappa A (2023).

**Abstract**

Mature cystic teratomas of ovary accounts for 10-20% of bilateral ovarian neoplasm. Majority of ovarian mature cystic teratomas are unilateral. Bilateral presentation accounts for only 10-15%. Our case is of 35-year multiparous women presented with chief complaints of abdominal pain. Imaging methods like USG abdomen and pelvis, MRI revealed presence of bilateral cystic ovarian masses suggestive of bilateral teratomas. On gross examination showed bilateral cystically enlarged ovarian masses with abundant grey yellow pultaceous material, hair tuft and Rokitansky protuberance. Microscopically showed presence of ectodermal, mesodermal and endodermal elements in bilateral ovarian cysts.

**Keywords:** Mature cystic teratoma; Bilateral; Ovarian neoplasm.

**Introduction**

Mature cystic teratomas of ovary are most common benign ovarian neoplasm of reproductive age group [1]. It accounts for 10-20% of all ovarian neoplasms [2]. Most of them are asymptomatic or may present with complaints of abdominal pain when they enlarge. Mature cystic teratomas most commonly present as unilateral cyst, bilateral presentation of mature cystic teratoma is rare and accounts for only 10-15% [3]. Malignant transformation of mature cystic teratomas seen in 0.1-0.2% of cases.

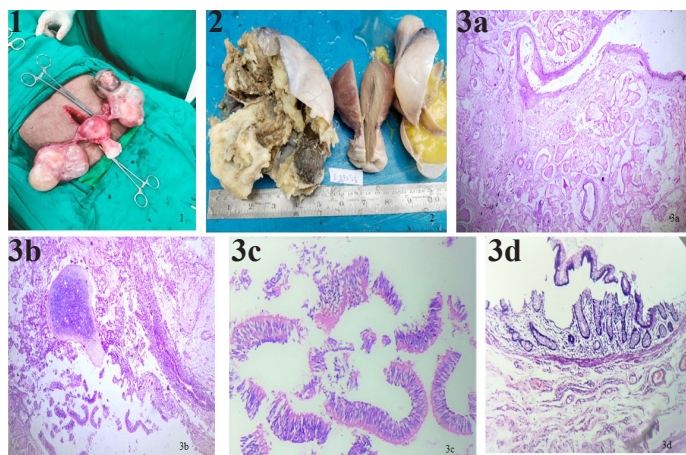
**Case presentation**

We present a case of 35-year multiparous women who presented with complaints of abdominal pain for 6-7 months. Ultrasound revealed bilateral cystic lesions of ovary. MRI pel-

vis showed well circumscribed, lobulated, heterogenous, predominant fat signal intensity lesions in bilateral adnexa. Left adnexal lesion is larger and measures 13.8 x 9 x 7 cm, smaller right adnexal lesion measures 9.3 x 7 x 7 cm. Few thick internal septae with focal internal soft tissue nodules identified in both adnexal lesions. Imaging features are highly suggestive of bilateral adnexal dermoid cysts. Patient underwent total abdominal hysterectomy with bilateral salpingo-oophorectomy and specimen was sent for histopathological examination. Intraoperative picture of bilateral cystic ovarian masses is shown in Figure 1. We received hysterectomy specimen with attached bilateral fallopian tubes and bilateral cystic ovarian masses. On gross examination uterus with cervix measured 8.5 x 5 x 4.5 cm. Bilateral ovaries were enlarged and cystic. Right ovarian mass measured 11.5 x 7 x 5.5 cm and left ovarian mass measured 13.5 x 8 x 7 cm. Cut section of both ovaries showed multiloculated cyst

**Citation:** Josephain K, Shankaralingappa A, Vijayan S, Yoga Purini P. Bilateral Ovarian Mature Teratoma in a Middle-Aged Female: A Rare Entity. *J Clin Med Surgery.* 2023; 3(2): 1113.

filled with yellow pultaceous material and tuft of hair (Figure 2). A thickened Rokitansky nodule was seen. Uterus, cervix and bilateral fallopian tubes were unremarkable. Microscopic findings of both ovarian cysts showed cyst lined by stratified squamous epithelium with pilosebaceous units. Also seen were other components like mature hyaline cartilage, adipose tissue, ciliated pseudostratified columnar epithelium, intestinal glands and specs of calcification (Figure 3a,3b,3c,3d). Along with mature cystic teratoma corpus luteal cyst was also identified. Cervix on microscopy revealed foci of Cervical Intraepithelial Neoplasia 1 changes.



#### Figures

**Figure 1:** Intraoperative picture of uterus and cervix with bilateral cystic ovarian masses.

**Figure 2:** Cut section of both ovaries showed multiloculated cyst filled with yellow pultaceous material and tuft of hair.

**Figure 3a:** Microscopic image of cyst wall lined by stratified squamous epithelium with underlying sebaceous glands (H&E, 200X).

**Figure 3b:** Microscopic image of ciliated pseudostratified squamous epithelium with seromucinous glands and foci of hyaline cartilage (H&E, 200X).

**Figure 3c:** Microscopic image of ciliated pseudostratified squamous epithelium (H&E, 400X).

**Figure 3d:** Microscopic image of intestinal epithelium and intestinal glands. (H & E, 200X).

#### Discussion

Ovarian teratomas are the most common germ cell tumors of ovary accounting for 95% of all germ cell tumors, 20% of all ovarian tumors. Bilateral occurrence is rare and seen in 10-12% of cases [3]. Different mechanisms for origin of mature cystic teratoma have been advocated and the most popular theory is the parthenogenic theory, which states that mass formation is activated from an unfertilized egg. This theory is reinforced by other studies which showed that ovarian dermoids have 46XX karyotype [4]. Surti et.al proposed five mechanisms for origin of ovarian teratomas and these include error of meiosis I, error of meiosis II, end reduplication of a haploid ovum, mitotic division of a premeiotic germ cell and fusion of 2 ova [5]. All

though ovarian teratomas can be seen from childhood to reproductive age group, mean age is 30 years, younger than epithelial ovarian neoplasms. Dermoid cysts are slow growing at a rate of 1.67-1.8 mm/year [6]. Benign teratomas are often discovered as an incidental finding during examination, imaging or abdomino-pelvic surgery. These tumors contain mature tissues originated from ectoderm, mesoderm and/or endoderm. The most frequent tissues encountered are ectodermal elements such as skin, hair, sweat and sebaceous glands.

In our case patient is in reproductive age and symptomatic, with pain abdomen. Imaging studies revealed bilateral ovarian masses. The differential diagnosis of multiple complex ovarian masses includes combination of hemorrhagic cysts, endometrioma, primary ovarian neoplasm or metastasis. There are studies which have shown that bilateral or multiple dermoid cysts have a greater tendency for ovarian germ cell neoplasms in future [7]. In addition to bilateral ovarian cystic mature teratomas, our patient also had Cervical Intraepithelial lesion 1 (CIN1).

#### Conclusion

Among the ovarian neoplasms, ovarian teratomas account for 20%, majority presents as unilateral ovarian teratomas. Bilateral presentation accounts for only 10-12%. In our case patient was of reproductive age with bilateral ovarian mature cystic teratoma.

#### References

1. Comerchi JT, Licciardi F, Bergh PA, Gregori C, Breen JL. Mature cystic teratoma: A clinicopathologic evaluation of 517 cases and review of the literature. *Obstet Gynecol.* 1994; 84: 22-8
2. Rha SE, Byun JY, Jung SE, Kim HL, Oh SN, et al. Atypical CT and MRI manifestations of mature ovarian cystic teratomas. *AJR Am J Roentgenol.* 2004; 183: 743-50.
3. Outwater EK, Siegelman ES, Hunt JL. Ovarian teratomas: Tumor types and imaging characteristics. *Radio Graphics.* 2001; 21: 475-90.
4. Flávio Garcia Oliveira, Dmitri Dozortsev, Michael Peter Diamond, Adriana Fracasso, et al. Evidence of parthenogenetic origin of ovarian teratoma: Case report, *Human Reproduction.* 2004; 19: 1867-1870.
5. U Surti, L Hoffner, A Chakravarti, et al. Genetics and biology of human ovarian teratomas: Cytogenetic analysis and mechanism of origin. *Am J Hum Genet.* 1990; 47: 635-643.
6. Caspi B, Appelman Z, Rabinerson D, Zalel Y, Tulandi T, et al. The growth pattern of ovarian dermoid cysts: A prospective study in premenopausal and postmenopausal women. *FertilSteril.* 1997; 68: 501-5.
7. EY Anteby, M Ron, A Revel, et al. Germ cell tumors of the ovary arising after dermoid cyst resection: A long term follow up study. *Obstet Gynecol.* 1994; 83: 605-608.